

FIRST AID AND MANAGEMENT PROCEDURES OF SEA TURTLES

Antonio Di Bello
DVM

Olimpia Lai
DVM, PhD



The project is co-funded by the European Union,
Instrument for Pre-Accession Assistance.



PREFACE

Sea turtles are exposed to many threats, from natural phenomena to anthropogenic factors. The diseases related to human activities are of many types: in the Mediterranean region the most frequent injuries result by accidental interaction with fishing activities. Very often, turtles are accidentally victims of long-lines, getting serious injuries in their digestive tract for hooks and lines ingestion, or damages in their fins for constriction by lines that can develop in necrosis and mutilation of limbs. Nets cause serious damages of limbs and external parts, and drowning syndrome caused by forced prolonged dives.

Other serious pathological events are related to accidental collisions with boats; contact with hydrocarbons and other pollutants discharged into the sea or by ingestion of floating waste (bags, bottles and other plastic items, fishing gear, etc..) cause poisoning and injuries.

Other accidents cause illness related to environmental, nutritional or metabolic factors (cold stunning, deficiency diseases, infectious and parasitic diseases, etc..).



The project is co-funded by the European Union,
Instrument for Pre-Accession Assistance.



1. FIRST AID PROCEDURES

In case of a stranded, drifting or accidentally caught sea turtle, the first aid provides a series of procedures really important to improve the recovery success.

First of all, it's important to place the patient in a plastic container, dimensioned for the animal's size and functional for the transfer, which allows the patient to maintain a ventral position avoiding compressing it or incorrect positions of limbs and head.

It is important to check the presence of foreign bodies that may block the upper respiratory tract of the animal, affecting breathing. In the tank the turtle lies on the plastron; the tank bottom should be covered by foam rubber or sponge or a towel folded in several layers.

Before moving a turtle in a rehabilitation center, it is important to record fresh identification data and information about finding. In particular, to note date and place of recovery, identification of the species and measurements of the curved carapace length (CCL n-t), general conditions of the animal and how it was found (accidentally caught by long-lines, nets or trawling, floating or washed up, etc..).



2. TRANSPORT OF TURTLES

During the transfer to the rescue center it's important to keep the head, neck, carapace and flippers moist or wet. Covering the body with a cloth soaked in sea water may be the easiest way to do so (figure 1).

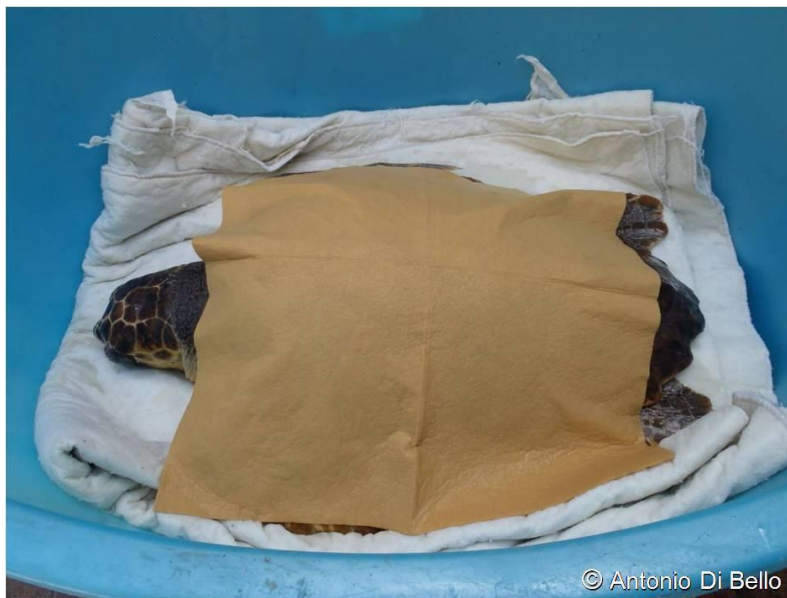

Figure 1: The turtle is placed in a plastic container on a towel folded in several layers. The body is covered with a wet cloth.

This method is easy and efficient if the ambient temperature is above 20°-22°C and if the trip is short; if the ambient temperature is low, a cold cloth might remove heat from the body of the animal, which can be quite dangerous especially in hypothermic and debilitated animals. To avoid this fact, it is useful to wet constantly the animal with small quantities of warm water (28°-30°C). Of course, it is important to control the amount of water in the bottom of the tank, as if too much, it could

compromise the breathing of debilitated animals.

During transport, it is appropriate to reduce stress for the animal: keep it in shadow, avoid noise, cover and protect its eyes, do not limit its ability to breathe properly, and avoid contact with other animals. In addition, it is requested to avoid animal movements into the tank, maintaining it in a normal ventral position without compressing it or assuming limbs and head abnormal positions (figure 2).



Figure 2: The turtle has taken an abnormal and dangerous position of the head that makes breathing difficult.

Once at the rescue center, the animal receives the first clinical evaluation and the first aid. A reactive animal can be immediately placed in a tank with water, checking if it breathes normally, otherwise in case of doubt, it is better to maintain the animal in a small amount of water, keeping the water level far below the nostrils.

3. HOW TO HANDLE THE TURTLES

For turtle and people safety, it's important to follow some correct procedures in order to raise, pull out of the tank and move a turtle. Depending the size, the animal is carried by one or two people. A single person can keep firmly the animal with one hand below the rear edge of the carapace, in correspondence of the caudal shield, and the other hand firmly to the cranial margin of the carapace, in correspondence with the nuchal shield (figure 3).



Figure 3: The image shows how a single person can take the turtle properly.

Another method for a single operator is to keep the animal with the plastron on his forearms, maintaining the opposite fin with his hand on the scapular-humeral region, tightening the animal to him, and with the other hand holding the turtle below the rear edge of the carapace (figure 4). This method is effective to reduce

stress to the animal but suitable only for individuals of less than 15 kilograms, otherwise it could be dangerous for the operator.

If the animal is large and heavy, two operators can move the animal from both sides, with their hands positioned cranially and caudally of the carapace (figure 5).



Figure 4: Another correct way to take a turtle.

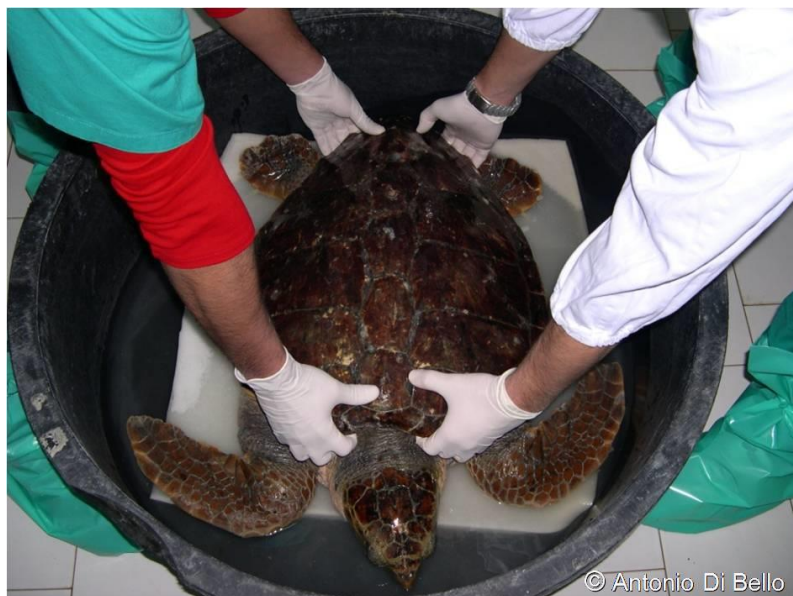

Figure 5: The proper way to take the turtle in two persons.

Always we must absolutely avoid taking or lifting a turtle by its flippers.

4. GENERAL CLINICAL EVALUATION

For a general evaluation, the animal is placed on a soft surface, keeping the body surface constantly wet.

The clinical observation assesses very carefully:

- nutritional conditions
- muscle tropism and tone
- appearance of the skin and external surfaces of carapace, plastron, and head
- inspection of natural openings and external mucous
- respiratory capacity and mode
- temperature
- sensorium level and reflexes
- strange attitudes
- swimming and floating mode

4.a. Nutritional condition

The nutrition status can be easily evaluated by inspection and palpation of subcutaneous tissue of neck region and soft tissues that surround the proximal part of limbs. In subjects presenting good nutrition, soft tissue at the base of neck, axillary and inguinal regions are generally prominent to palpation, showing soft-



elastic consistency due to the presence of adipose tissue (figure 6). In animals undernourished, axillary and inguinal regions appear sunken, the skin around the neck is not very elastic and the below muscles become evident (figure 7).



Figure 6: Turtle in a good nutrition status: it is evident abundant fatty tissue under the skin of the neck and axillary region.

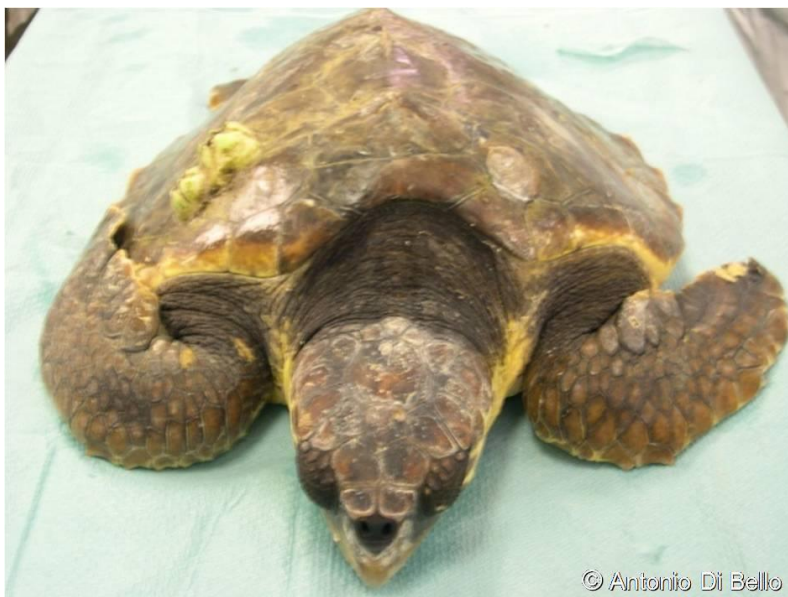

Figure 7: Turtle in a poor state of nutrition.

4.b. Muscle tropism and tone

Tone and muscle tropism can be assessed through examination of front flippers: under normal conditions the proximal parts of limbs are surrounded by strong muscle bellies; in debilitated animals, tone and tropism muscle may appear really reduced and the palpation of limbs allows to perceive easily the skeletal structures below the skin, sparsely covered with muscle structures.

4.c. Appearance of the skin and external surfaces

The inspection of skin and of external surfaces of the animal is fundamental and must be done very carefully. First of all, it is necessary to evaluate the presence of ectoparasites, their localization and extension, as well as the identification of types (barnacles, limpets, leeches, algae, etc..) (figure 8). If present in excessive amounts, they may be a first sign of the turtle's discomfort because they tell us that the animal has recently been moving slowly. Because ectoparasites are very tenaciously attached to the surface of the animal, their removal should not be done mechanically using knives, chisels or other tools that could be traumatizing, as they risk to severely damage skin and shield. For a removal without trauma, it is enough to maintain the patient for two or three days in fresh water, resulting in death and detachment of all ectoparasites. Of course this is possible after to complete clinical evaluations and determine that the turtle can swim in a tank.

The analysis of external wounds helps to understand cause and time of them. Injuries located on skull and carapace are more frequently due to accidental trauma with boats or rocks during storms, if the animal was weakened (figure 9).



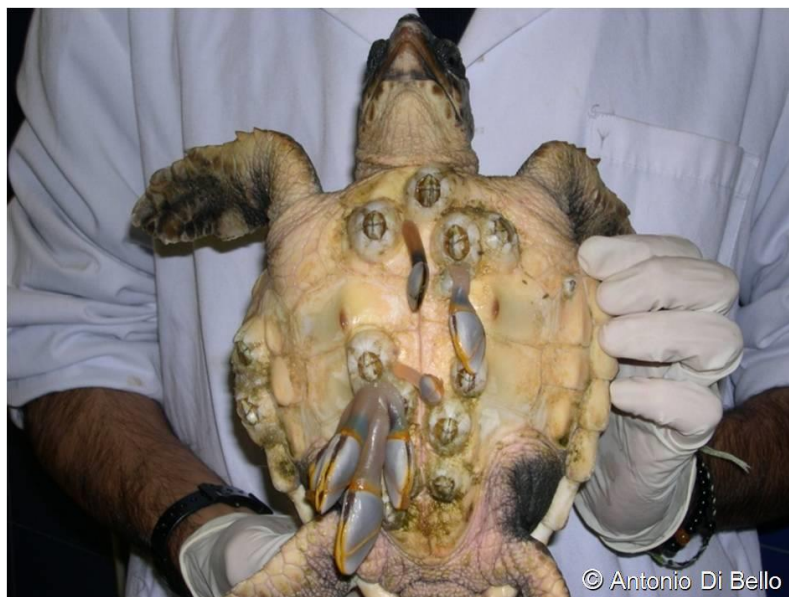

Figure 8: Turtle with many barnacles and goose barnacles attached to the plastron.

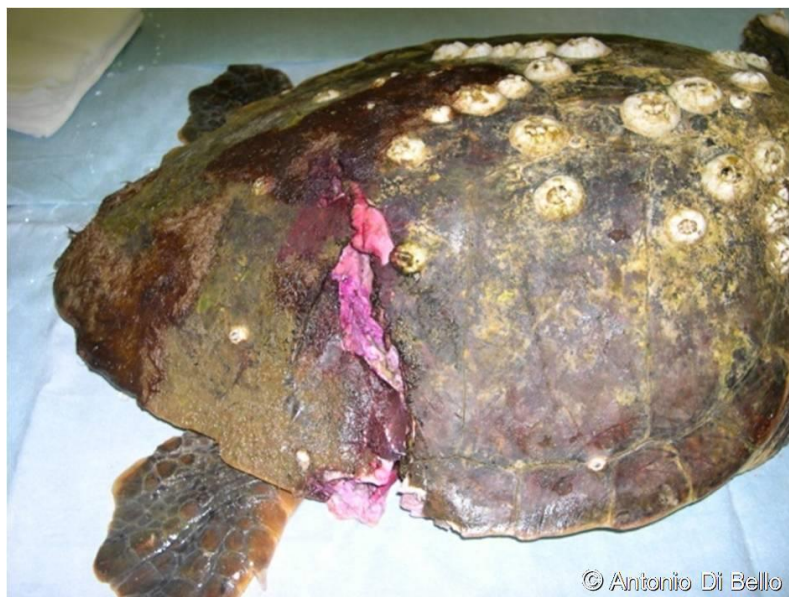

Figure 9: Wide and deep injury of the carapace caused by the impact with a boat.

Very serious neck and limbs injuries can be caused by lines, ropes, plastic bags or other foreign waste floating in the sea (figure 10). Skin lesions, localized or diffuse, can be caused by primary and secondary bacteria and fungi growth, in this case it is important to carry pads and skin scrapings for identification of causative agent.

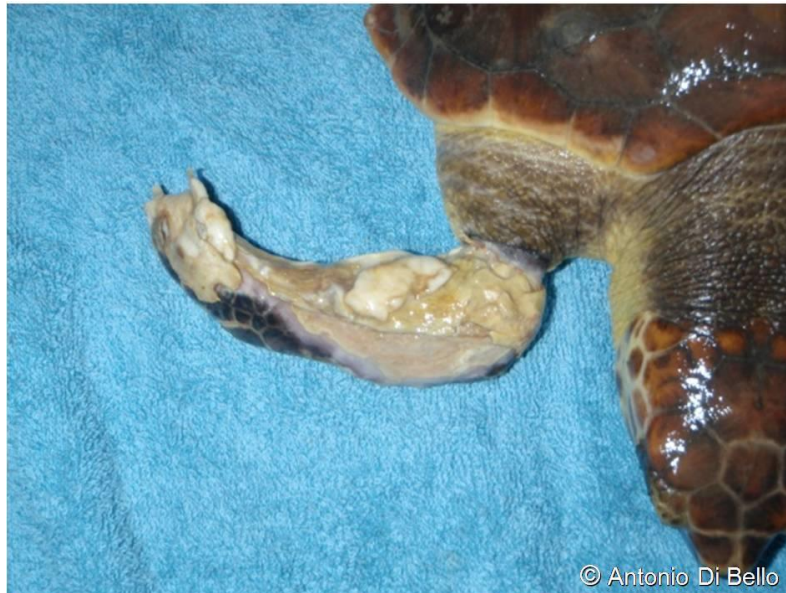

Figure 10: Tissue necrosis of the flipper caused by fishing lines constriction.

4.d. Inspection of natural openings and external mucous

External inspection of the mouth allows to evaluate the presence of lines or other foreign bodies, wounds and sores in the mouth corners, as the poor status of nutrition, generally connected with the presence of a hook or a line ingested for a while (figure 11).

The deep inspection of the oral cavity helps to detect hooks anchored in the proximal part of the esophagus, inflammations and ulcerations of the mucosa or

other injuries; their nature should always be determined through the execution of sterile swabs and laboratory tests (figure 12).

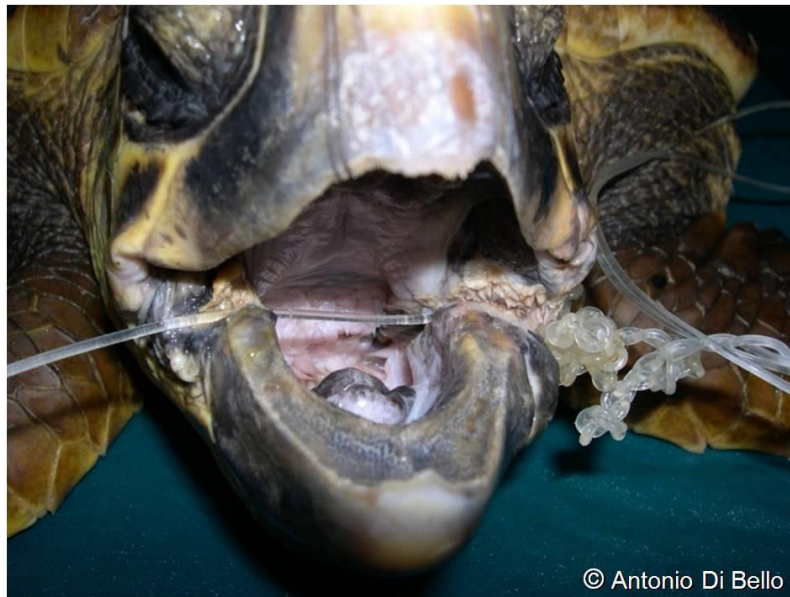

Figure 11: Long line coming out of mouth and has caused serious injury and necrosis by compressing the lower jaw.

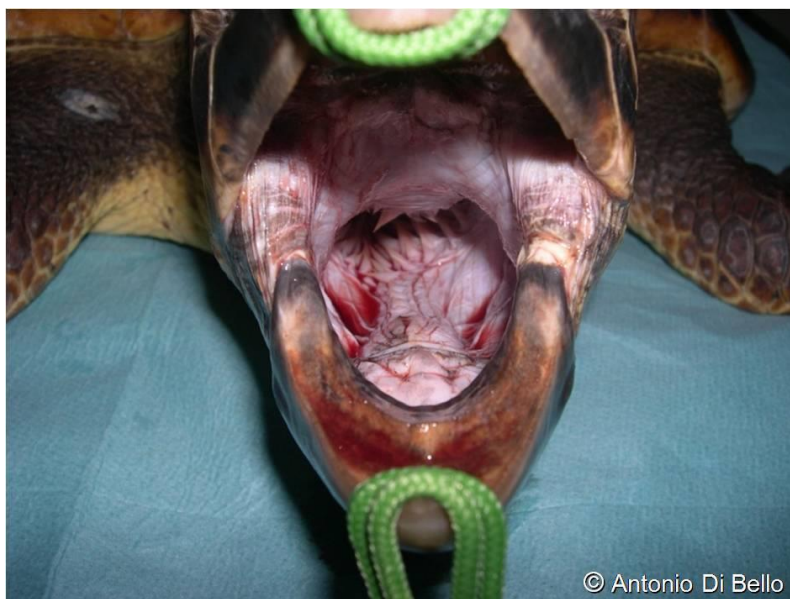

Figure 12: The deep inspection of the oral cavity reveals a bleeding in the esophagus.

The external inspection of cloacal opening evidence if there is a line or a prolapse or edema of the surrounding soft tissues (figure 13).

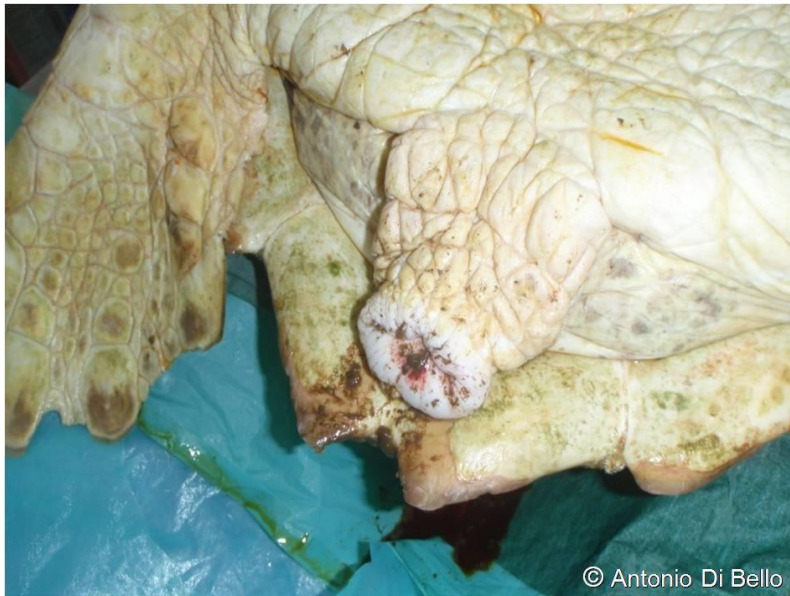

Figure 13: Slight prolapse of the cloaca and edema of the surrounding soft tissues caused by a longline crossing the intestine.

4.e. Respiratory capacity and mode

When out of the water or in a stressful situation, turtles may alter the frequency and manner of their breathing, for this it is important to observe if inhalation and exhalation phases look limited, or they produce breath sounds or biological material or foreign objects from the mouth or nostrils (figure 14).



Figure 14: Foam spilling from the nostrils due to a pulmonary edema, caused by a prolonged apnea in the trawler net.

4.f. Temperature

The measurement of the internal temperature can be recorded by infrared thermometers or a endocloacal probe; for an efficient metabolism, the body temperature should not be lower than 18 ° C. During winter, it is very frequent to recover specimens in hypothermia, or cold-stunning, this often affects small turtles as a result of sudden reduction of temperature, for sudden weather changes. In these circumstances animals are slaughtered, lethargic, bradycardic and bradipnoic. As hypothermia causes lowering of metabolism, reptiles are not able to respond to any drug treatment, so it is necessary to maintain their body temperature at an optimum level to ensure a good metabolism, between 25 ° and 30 ° C.



4.g. Sensorium level and reflexes

The assessment of the sensorium status is carried out through reflexe stimulations and physiological reactions. Reflection tests are retraction of neck and fins, opening of the mouth, blink reflex, as cloacal and tail ones. Normally after a slight traction of the head or of the end of a fin, the animal instinctively retracts the part. Another reaction is stimulated by lifting with caution the top of ranfotec: the animal often reacts instinctively arching high the neck and opening the mouth, this reaction is also very useful to inspect the oral cavity. Blink reflex is stimulated by tapping lightly with a soft object (eg. a wet cotton swab) the lateral or medial margin of the eyelids: to this stimulus the animal normally reacts with the quick closure of its eyelids. In normal conditions, a gentle introduction of the tip of a finger or a wet cotton swab into the cloaca or moving laterally its tail, the animal reacts by contracting the cloacal sphincter and ventral bending forward the tail (figure 15).

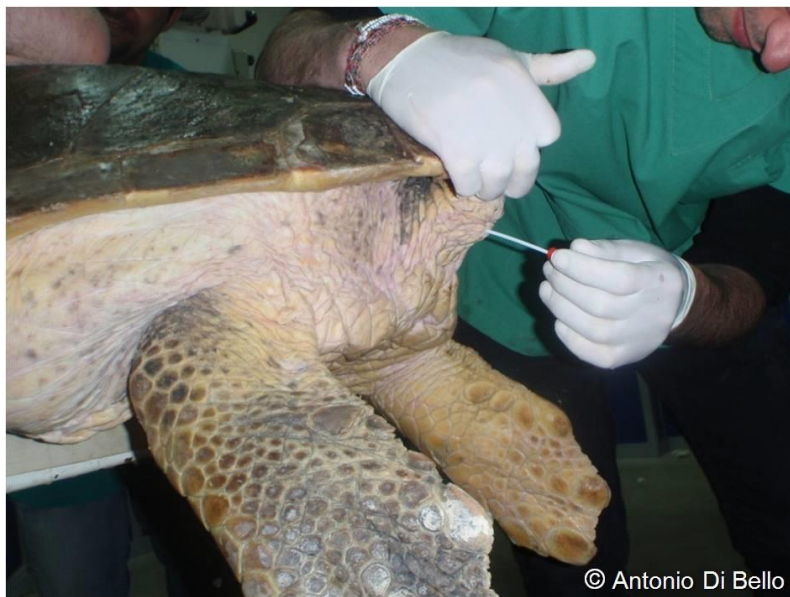

Figure 15: Evaluation of cloacal reflex with a wet cotton swab.

When one or more of these reflexes are delayed, not evident or even absent, this is a sign that the animal is in severe illness and prostration.

These important assessments are followed by morphometric and weight measurements.

4.g. Swimming and floating mode

If no clinical signs are evident, the patient is checked in its tank, in order to assess its breathing, movements in water, attitude and ability to dive and to emerge without difficulty.



5. LABORATORY INVESTIGATION

The next very important step is the sampling and analysis of biological samples to complete the study of the state of health of the animal.

5.a. Restraint techniques

To take samples of biological material but also in many phases of clinical examination, it is important to restrain the turtle so that it is not damaged, that the animal does not cause operator injury and even that it does not receive too much stress. To that end, first of all it is appropriate to cover the eyes of the animal so that it is quieter. To do this you can use a cotton sock, preferably dark colored, which is threaded on the head, or you can wrap the head with a selfadhesive elastic bandage, taking care not to cover the nostrils. To restrain properly the turtle on the examination table, the operator must stand behind the animal and take the front flippers firmly at the humerus-radio-ulnar joint. Resting his elbows on the carapace, the operator press down slightly and at the same time with hands keep the front flippers pulled back and close to the carapace (figure 16-17). In larger animals is appropriate that the operator lean his bust on the dorsal part of the carapace, and with his weight keep firm the animal.





Figure 16: Positioning of the operator to properly restrain the turtle (frontal view).

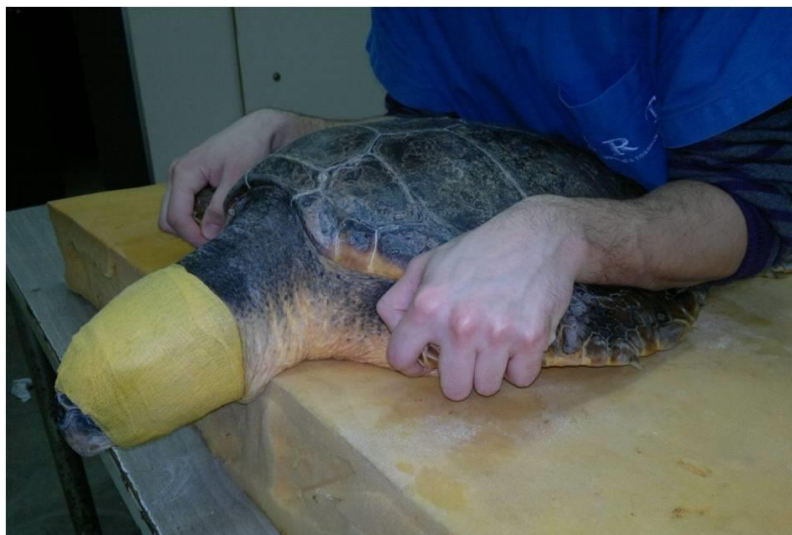

Figure 17: Positioning of the operator to properly restrain the turtle (lateral view).

5.b. Venipuncture for blood sampling

Biological samples and analysis include blood samples for biochemical assessment and emocromocitometry by cervical venous sinus or jugular veins. These procedures



require a minimum of experience and manual skills. The use of the supravertebral cervical venous sinus is realized containing the animal with the neck extended and slightly down. The needle connected to the syringe is introduced into the dorsal surface of the neck, in the paramedian position between cervical spine and cervical biventer muscle. The needle is inserted with an angle of about 45-60 degrees in the skin, either on one of the two sides, in an area between the neck and the cranial edge of the carapace (figure 18).

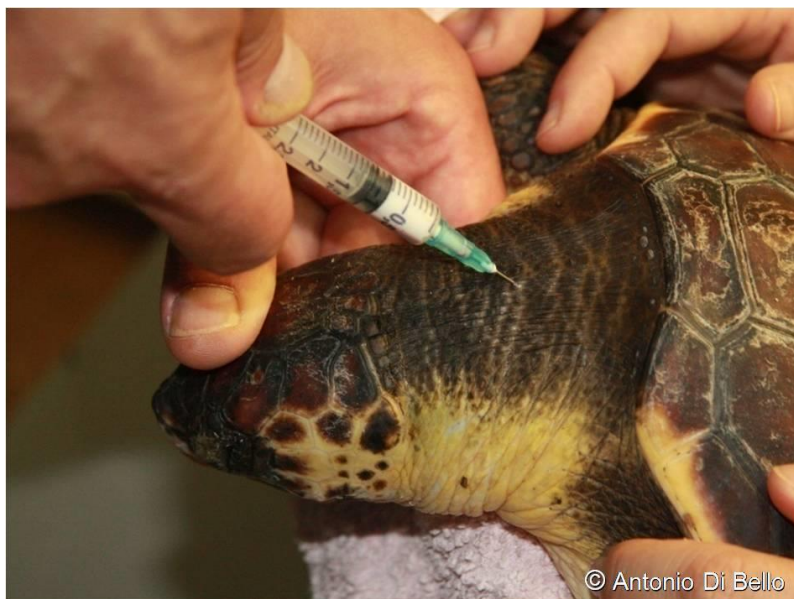

Figure 18: Puncture of supravertebral cervical venous sinus.

The blood test can be done easily from the lateral occipital sinus. For access to the lateral occipital sinus, the head is extended and slightly ventroflexed. The venous sinus is located paravertebrally, between cervical spine and lateral surface of the neck; the needle is introduced perpendicularly to the skin (Figure 19).

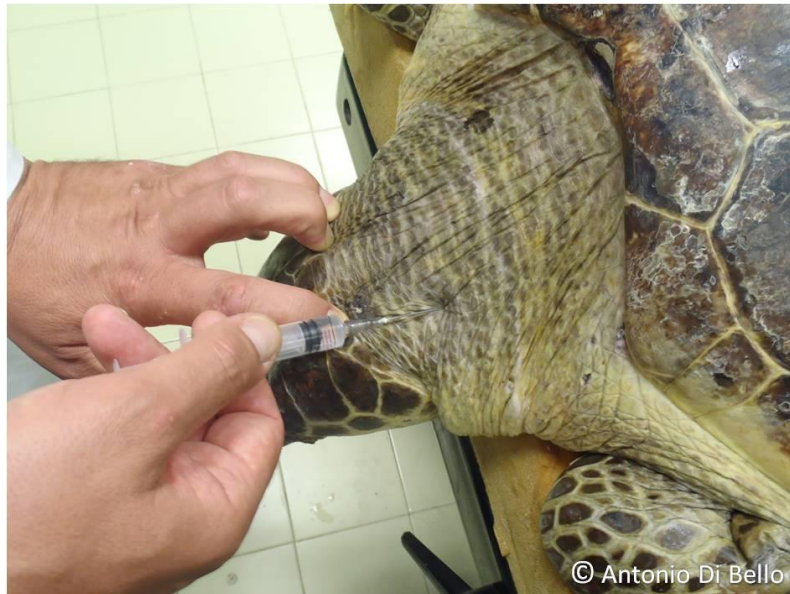

Figure 19: Puncture of lateral occipital sinus.

The jugular vein sample is obtained containing the animal with the head in extension and inserting the needle of one of the two sides of the neck, in a cranio-caudal direction and with an angle of approximately 30 degrees to the skin. The needle is inserted in the depression of the neck just below the transverse cervical muscle (figure 20).

By the same way, when needed, fluids and drugs can be administered in bolus or with continuous controlled infusion.

When intravenous route is difficult or impossible to reach, fluids can be dispensed by via intracoelomic, subcutaneous or intraosseous bridge between carapace and plastron.



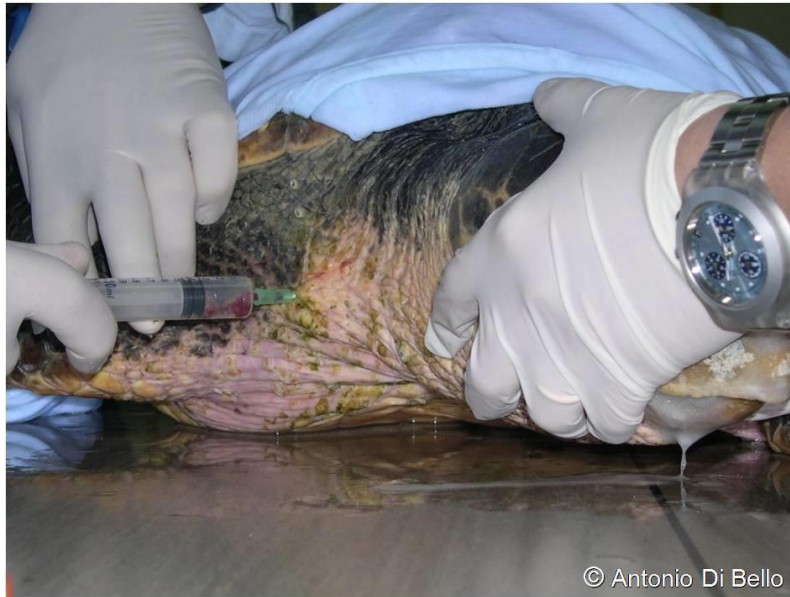

Figure 20: Puncture of jugular vein.

5.c. Other biological samples

Faecal samples can be obtained from the bottom of the tank, immediately after defecation, with a highly textured screen; an amount of feces can be taken directly from the rectum with a digital exploration of the cloaca (Figure 21).

Oral, conjunctival and skin samples are taken for virological, bacteriological and mycological analysis.



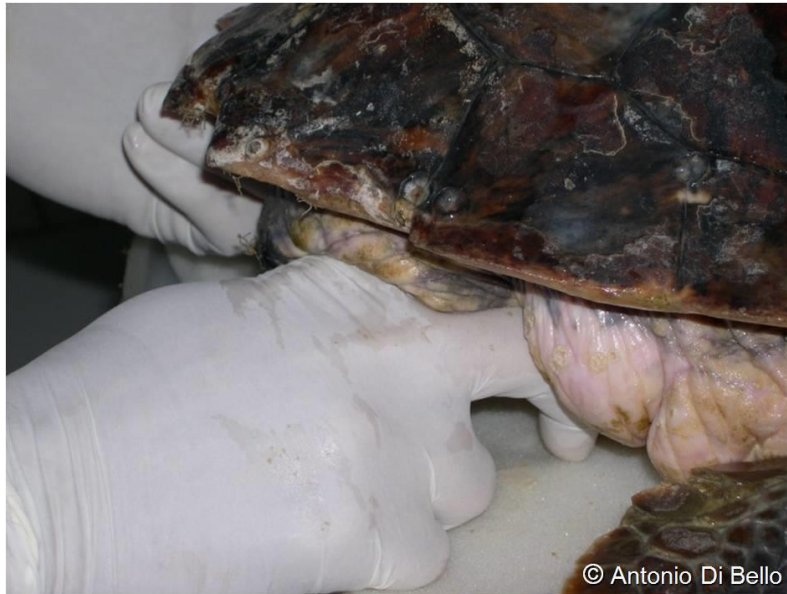
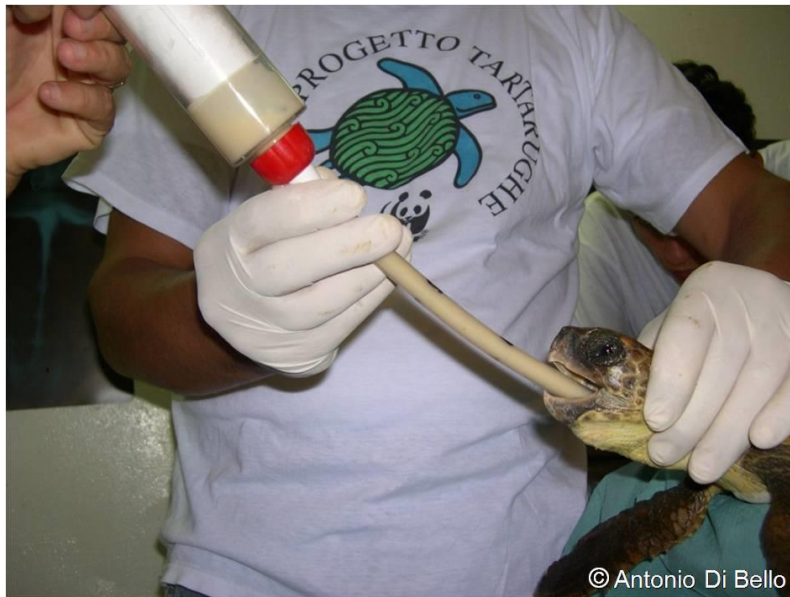
Figure 21: Faecal sampling directly from the rectum.

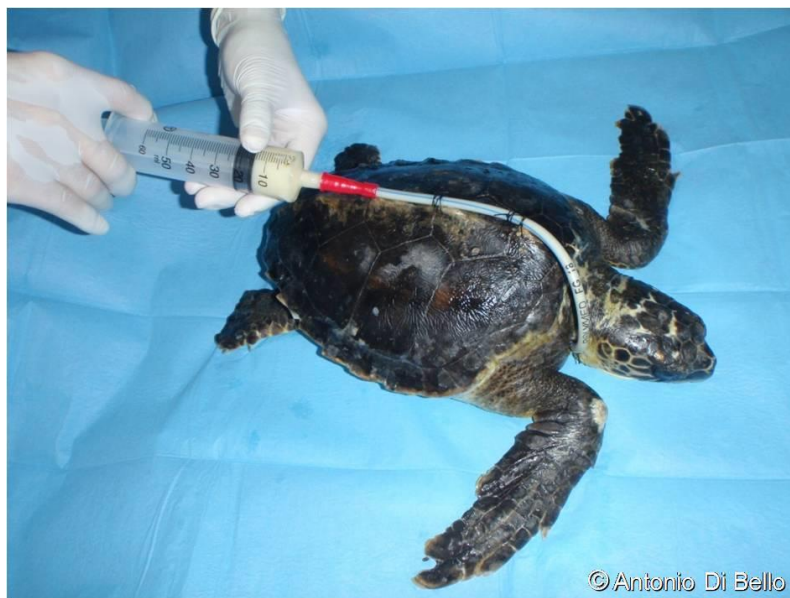6. FEEDING TECHNIQUES

Except particular cases, it is appropriate to feed the patient daily, still immediately after surgery. In case of lack of appetite or prolonged fasting, it's better to force feed the patient, until the spontaneous feeding. This procedure is realized by introducing an oral gastric probe to administrate homogenized food. The forced tube feeding is a very stressful procedure for turtles and operators, and risks of damages to oesophagus (figure 22). To assure a less traumatic feeding procedure, it's recommended to use an oesophagogastric probe inserted through a temporary stoma, realized in the lateral surface of neck (figure 23).



© Antonio Di Bello

Figure 22: Execution of forced tube feeding in a small turtle.



© Antonio Di Bello

Figure 23: Daily force feeding through a oesophagostomy tube.



The project is co-funded by the European Union,
Instrument for Pre-Accession Assistance.

7. BIBLIOGRAPHY

Mader, D.R. 2006 Reptile medicine and surgery, second edition. Saunders Elsevier Inc., St. Louis (Missouri, USA).

Mc Arthur, S., Wilkinson, R., Meyer, J. 2004. Medicine and Surgery of Tortoises and Turtles. Blackwell publishing Ltd, Oxford (UK)

Norton, T.M. 2005. Chelonian emergency and critical care. Seminars in Avian and Exotic Pet Medicine. 14: 106-130.

Wyneken, J. 2001. The Anatomy of Sea Turtles. NOAA Technical Memorandum NMFS---SEFSC---470. <http://csi.who.edu/biblio/anatomy---sea---turtles>.



8. ANNEX I

PRELIMINARY DATA REPORT OF RECOVERED SEA TURTLES

Date ____/____/____ place of recovery _____

Species: Caretta caretta Other _____ CCL _____ cm

Mode of recovery: Stranding Adrift at sea Caught accidentally with:

- Longline
- Trawling
- Drift net
- Gill net

External presence of:

- Barnacles No. _____
- Goose barnacles No. _____
- Algae
- Mud
- Other _____

Presence of external foreign bodies:

- Hook in the mouth
- Line from the mouth
- Line from the cloaca
- Line entangled
- Net entangled
- Other _____

Nutritional condition:

- Excellent Good Fair Scarce

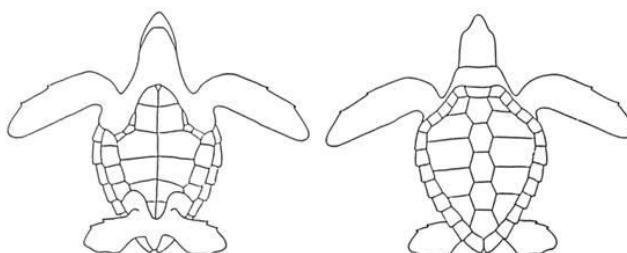
Apparent general health:

- Good condition
(the turtle moves energetically, is responsive, no evident problems)
- Average condition
(the turtle stand still, only reacts when stimulated, presents external injuries, etc.)
- Bud condition
(the turtle does not react when stimulated, presents serious external injuries, etc.)

External injuries:

- Head (superficial / deep)
- Neck (superficial / deep)
- Carapace (superficial / deep)
- Plastron (superficial / deep)
- Flippers (superficial / deep)
- Other _____

Mark location and extent of the lesions



The project is co-funded by the European Union, Instrument for Pre-Accession Assistance.

